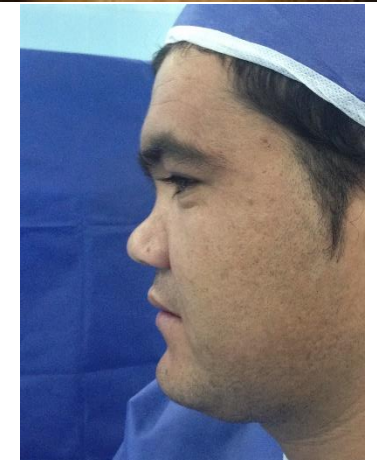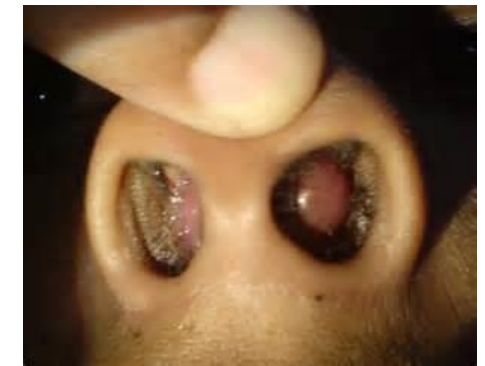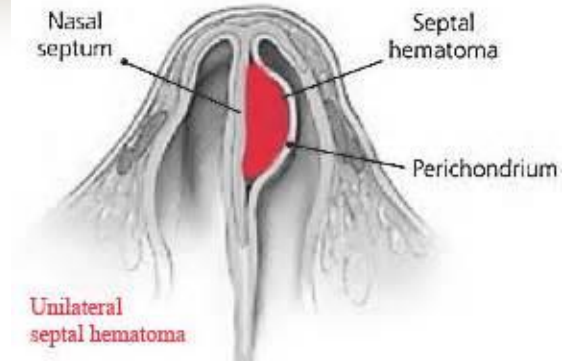


Septal collapse (saddle nose)



The cartilaginous septum can be necrosed following:

- repeated trauma
- an untreated nasal septal haematoma
- after extensive nasal surgery
- Septal abscess
- Some chronic inflammatory conditions, e.g. nasal granulomatosis, syphilis, and tuberculosis
- cause aesthetic deformity and may septal necrosis with 'saddling'
- May lead to nasal obstruction.



Septal collapse (saddle nose) Treatment

- Treatment is difficult and may require extensive surgery to both the cartilage and the nasal bones—
‘augmentation
septo-rhinoplasty

